

The ageing face

JOHN M HILINSKI AND DEAN M TORIUMI

Introduction	3068	Complications	3074
History of ageing face surgery	3068	Key points	3075
Biology of ageing	3069	Best clinical practice	3075
Clinical evaluation	3070	Deficiencies in current knowledge and areas for future research	3075
Surgical technique	3071	References	3076
Submental liposuction and platysmaplasty	3073		

SEARCH STRATEGY AND EVIDENCE-BASE

The data in this chapter are supported by a Medline search using the key words rhytidectomy, facelift and facial rejuvenation. All evidence is based at levels 3/4.

INTRODUCTION

As populations expand and life expectancy increases, growing numbers of people are seeking methods to counteract the ageing process. Over the past three decades, refinements in surgical techniques have enhanced our ability to manage the ageing face patient. The goal of ageing face surgery is to achieve a natural, rejuvenated, youthful appearance. Higher patient expectations and increasing demand for comprehensive rejuvenation have led to today's multi-faceted approach to the ageing face. This chapter focuses on rhytidectomy, or facelift surgery, which is a central component in ageing face surgery. Other important considerations, such as laser skin resurfacing and blepharoplasty are covered in Chapter 58, Laser principles in Otolaryngology, head and neck surgery; and Chapter 221, Blepharoplasty.

HISTORY OF AGEING FACE SURGERY

The history of ageing face surgery dates back to the beginning of the twentieth century. Average life spans

increased sufficiently around this time, such that individuals began manifesting signs of ageing for the first time. Issues of senescence became commonplace throughout society. Surgeons were soon honouring patient requests for procedures that would help counter the ageing process. Early pioneers of plastic surgery were commonly referred to as 'featural surgeons', reflecting the prevailing negative attitude toward 'unnecessary' surgery. Although most respected members of the medical community shunned this type of surgery, others recognized its benefits and secretly practised on growing numbers of hopeful patients. Unfortunately, public disdain curbed widespread acceptance of plastic surgery and limited attempts at documenting these early efforts.

The German surgeon Erich Lexer (1867–1937) is widely credited as the first individual to describe a rhytidectomy, doing so in 1906. Using S-shaped incisions, Lexer excised skin paddles in strategic temporal and preauricular locations to rid patients of lateral rhytids or wrinkling, hence the term rhytidectomy. Skin excision was fairly conservative and was performed only to facilitate closure. Not surprisingly, Lexer's technique resulted in only a subtle improvement. In the ensuing years, other European

surgeons, including Eugen Hollander (1912), Suzanne Noel (1920) and Jacques Joseph (1921), reported their experience with minor variations of the same technique. American participation in the evolution of rhytidectomy was virtually independent of European contributions. The first American to publish on the technique was Charles Conrad Miller (1907), also one of the first surgeons to provide anatomical drawings guiding incision placement. Another American, Adalbert Bettman (1920), introduced the continuous pre- and post-auricular incision that later became known as the contemporary rhytidectomy incision.

Subsequent advances in anaesthesia safely permitted more extensive undermining beyond the preauricular margin. Eventually, the elevation of long skin flaps over the entire lower face and upper neck became routine practice. This so-called 'long flap' technique combined with Bettman's continuous incision to usher in the era of the subcutaneous rhytidectomy. The subcutaneous technique quickly gained popularity because it was technically straightforward and relatively safe. Unfortunately, tension was placed exclusively on the skin flap, often leading to an 'operated look'. Results were also short-lived due to what we now recognize as skin creep and rebound stretching. Despite these drawbacks, no other significant contributions were made during this period. Thus, subcutaneous rhytidectomy remained as the standard in ageing face surgery for nearly 50 years.

The 1970s witnessed two major advancements in ageing face surgery. The first was introduced by Tord Skoog¹ in 1974. Until that time, fear of injuring neurovascular structures precluded attempts at dissecting deep to the subcutaneous layer. Skoog pointed out the existence of a safe dissection plane below a tough fascial layer spanning the face. He also highlighted the fact that this plane is continuous with the subplatysmal plane in the neck. By developing a 'short flap' along this plane, the fascial layer could be used as a 'girdle' to lift the skin and subcutaneous fat together. Skoog reasoned that suspension of this composite unit, as opposed to a skin only flap, would generate less tension on the skin. This translated into less visible scarring and longer-lasting results. For the first time, Skoog demonstrated how the lower face and upper neck could be safely rejuvenated as one anatomic unit without detaching the skin.

The second major advancement was the description of the superficial musculoaponeurotic system (SMAS), by Mitz and Peyronie² in 1976. This landmark publication validated the fascial layer referred to by Skoog and detailed its anatomic relationship with other facial structures. It demonstrated the SMAS to be a condensed fibrous mesh layer situated below the subcutaneous fat and over the facial muscles. A series of transverse fibrous septations between the SMAS and skin helped in transmitting facial expression. Because the ageing process weakened elasticity of these fibrous septations, Mitz and Peyronie contended that suspension of the SMAS could aid in reestablishing a youthful facial appearance.

Description of the SMAS has served as a catalyst for evolution of a variety of rhytidectomy techniques over the past 25 years. Most variations involve some form of SMAS manipulation as part of the surgical technique. Much of the debate today focuses on the extent of dissection below the SMAS. For instance, some surgeons argue that dissecting further medially (such as in extended SMAS and deep plane techniques) provides additional benefit. Thus far, convincing evidence does not exist to support this claim. Most facial plastic surgeons would agree that the traditional SMAS technique provides excellent reliable results and remains the standard in ageing face surgery.

BIOLOGY OF AGEING

Facial ageing involves an array of biological changes influenced by intrinsic and extrinsic mechanisms. Intrinsic ageing is primarily characterized by atrophy of the facial skin and subcutaneous fat, as well as volume changes in the facial skeleton. Numerous histological transformations occur within the epidermal and dermal layers of skin. Ageing results in a significant decline in the density of keratinocytes and melanocytes within the epidermis.³ This contributes to thinning and abnormal pigmentation of the skin. Within the dermis, elastic fibres begin to disappear resulting in deficient tissue recoil and manifesting as excess wrinkling. Retraction of dermal papillae and rete ridges causes flattening of the dermal-epidermal junction. In combination, these changes result in the decreased capacity to retain moisture and lead to dryness that typifies aged skin.

Atrophy of subcutaneous fat is a hallmark of facial ageing. The supporting fascial attachments around the fat pads also begin to weaken with age. Gravitational forces gradually redistribute these tissues in a more inferior and lateral direction. Consequently, entire subunits, such as the malar fat pad and jowl, become ptotic and contribute to a tired facial appearance.

As we age, volume changes occur in the facial skeleton due to continuous remodelling. Relative changes can be seen in terms of both volume reduction and expansion. An appreciable reduction in height occurs with modest increases in width and depth.⁴ For example, over time, the vertical height of the maxilla decreases while the width of the orbital bones increases. Such changes lead to a disproportionate balance between the available bony surface area and soft tissue coverage. This results in inferior displacement of the cheek pad and skin. This same process accounts for jowl formation and sagging along the neckline.

Extrinsic mechanisms of ageing most commonly involve skin damage sustained from solar exposure, known as photoageing. The process of photoageing is widely known to amplify the changes resulting from intrinsic mechanisms noted above. In addition, photoageing causes disorganization of dermal elastic tissue fibres, termed elastosis, which contributes to further development of fine skin wrinkles.

CLINICAL EVALUATION

Achieving success in ageing face surgery begins with proper patient selection. One of the most critical factors to consider is the patient's psychological motivation for surgery. Numerous studies^{5,6} demonstrate that patient psychology is a significant determinant of postoperative satisfaction in ageing face surgery. The patient who has a stable self-image and internal desire for a more youthful appearance is more likely to be satisfied with the postoperative result. In contrast, the patient seeking surgery to remedy a situational or social dilemma may have unrealistic expectations and heralds unhappy results for themselves and the surgeon.

It is imperative that patient and surgeon are in complete agreement on the indications for surgery and the resulting anticipated changes. Rhytidectomy is an excellent technique to correct visible signs of ageing in the lower two-thirds of the face and upper neck. This includes redundant facial skin and deep rhytids, jowling or loss of a well-defined mandibular contour, and modest improvement of prominent nasolabial folds. Patients should be counselled that rhytidectomy is not effective for superficial rhytids resulting from solar damage or minor depressions secondary to acne scarring. These abnormalities are more appropriately treated with adjunctive techniques, such as laser resurfacing or dermabrasion.

As with any elective procedure, overall good health is a prerequisite in ageing face surgery. Preoperative evaluation includes a thorough history and review of systems to screen for potential complicating factors. Many patients consider rhytidectomy following significant weight loss. If further weight loss is planned or a history of repeated weight loss and gain is suspected, surgery should be delayed until a plateau has been reached. Patients with a history of coronary artery disease, hypertension, pulmonary compromise and hepatic or renal insufficiency should be cleared by the appropriate medical specialist in advance. Relative contraindications to rhytidectomy include predisposition to poor wound healing, as seen in diabetes mellitus, chronic steroid use, connective tissue disorders (such as Ehlers–Danlos syndrome) and past radiation therapy. An absolute contraindication to surgery is a history of a bleeding diathesis.

All medications containing aspirin and nonsteroidal antiinflammatory agents are discontinued at least three weeks prior to surgery to minimize bleeding. It is important to enquire about use of supplemental vitamins (particularly vitamin E) and homeopathic preparations (including ginkgo biloba and garlic). These medications are in widespread use but rarely disclosed voluntarily by patients and can contribute to unexpected bleeding.

A history of tobacco use is particularly relevant in the assessment of the ageing face patient. It has been estimated by Rees and Aston⁷ that smokers have a 12 times increased risk of skin slough following rhytidectomy compared with nonsmokers. This is attributed to a

higher incidence of haematoma formation and vasoconstriction. Although long-term effects of smoking on skin cannot be negated by perioperative cessation, surgical complications can be reduced by smoking cessation within two months of surgery.

There is no ideal age when considering timing for ageing face surgery. In general, individuals in their middle to late ages are considered excellent candidates. Chronologic age alone should not be used as the qualifying criteria. More importantly, consideration is given to the visible degree of ageing in a particular individual. Patients demonstrating mild to moderate degrees of ageing are more likely to achieve a natural, rejuvenated appearance. Signs of advanced ageing, such as extreme skin sagging, are more difficult to correct and will limit expected improvement. Rhytidectomy is often an operation of compromise. Dramatic improvement can be made in one region, however, this may occur at the expense of suboptimal change in another. In patients with advanced signs of ageing, it is beneficial to strive for less dramatic but more natural change initially, with further refinement at a later date if necessary.

Physical examination begins with assessment of the patient's skin type. An ideal candidate for rhytidectomy is an individual with fair, medium-thickness skin. Dark patients usually have thicker skin and enjoy less dramatic improvement. The increased weight of their skin also results in more postoperative skin relaxation. The presence of a moderate amount of skin elasticity is beneficial. Less elastic skin can be tightened by rhytidectomy, but the duration of improvement may be less than satisfactory. A modest degree of subcutaneous fullness is also desirable, particularly in the midface. This reflects a healthy adipose tissue layer and contributes to a more youthful look.

Facial skeletal structure can help predict a more or less favourable surgical outcome. Patients with a strong facial skeleton usually demonstrate more obvious improvement. Well-defined bony contours provide excellent support for skin redraping and accentuate desirable facial features. Patients with mid-facial hypoplasia are poor candidates for rhytidectomy alone and typically require adjunctive procedures. Similarly, patients with microgenia and poor chin definition require chin augmentation in conjunction with rhytidectomy to achieve enhanced results.

Many rhytidectomy patients express concern regarding skin laxity and fullness in the submental region. This is best appreciated on a profile view by assessing the cervico-mental angle. The submentum should be palpated to determine relative contributions from redundant skin, fatty tissue and platysmal banding. Redundant skin alone can usually be addressed with standard rhytidectomy technique by suspension of the cervical skin. Excess fatty tissue is most effectively treated by submental liposuction. Patients with prominent platysmal banding require muscle tailoring, or platysmaplasty, to attain a more favourable cervico-mental angle. In patients with extreme fatty

deposition, platysmal banding may not be appreciated until after liposuction has been performed. Thus, patients should be counselled that platysmaplasty may be indicated in addition to submental liposuction. It is worth noting that a subgroup of patients have an inherent anatomic limitation to the degree of improvement that can be realized in the submental region. These patients have an abnormally low positioned hyoid bone and are considered less than ideal candidates for surgery. Such patients should be thoroughly counselled that rhytidectomy, even in conjunction with liposuction and platysmaplasty, will not significantly affect their submental profile view.

Preoperative photographs are taken with standardized 1:8 full-face frontal, lateral and oblique views. Digital imaging is often useful in demonstrating to the patient realistic changes that can be expected following surgery.

SURGICAL TECHNIQUE

This section outlines general steps in surgical technique for SMAS rhytidectomy and submental liposuction or platysmaplasty.

The patient is marked preoperatively in the sitting upright position. Areas of special concern are highlighted, as well as anatomic landmarks such as the geniomandibular groove, mandibular border and submental triangle. A preoperative intravenous dose of an appropriate anti-staphylococcus antibiotic is then administered.

We prefer to perform rhytidectomy under local anaesthesia with intravenous sedation. This anaesthesia is well tolerated by the patient and the facelift operation is easily performed after performing appropriate anaesthetic injections and nerve blocks. Anaesthetic solution containing 1:100,000 epinephrine is infiltrated along the pre- and post-auricular borders and in a fan-like fashion beneath the facial and upper cervical skin flaps. If liposuction or platysmaplasty is planned, additional solution is infiltrated throughout the submental region. In multiple procedure cases that may run for an extended period of time, a general anaesthetic may be more appropriate. The endotracheal tube is prepped into the surgical field and positioned to allow side to side movement during the operation. The entire face, neck and scalp are prepped and draped in the usual sterile manner.

Careful incision design and placement are vital to achieving natural appearing results in rhytidectomy. The ideal incision camouflages scar formation, minimizes changes in the temporal and post-auricular hairline, and avoids distortion of the earlobe. An oblique incision begins in the temporal hair tuft region and varies for the individual patient. If a low temporal hairline is present, the incision is placed within the hair tuft to raise the hairline to a normal position postoperatively. If a normal or elevated temporal hairline exists, the incision is designed to run directly on the hairline to avoid raising it any further. The incision extends posteriorly 2–3 cm, gently curving into

the temporal hair. It is then redirected inferiorly toward the root of the helix and into the preauricular crease.

A post-tragal incision is used in most female patients (**Figure 222.1**). The incision is positioned 2–3 mm onto the posterior tragal surface and not deep toward its base. It exits at the inferior margin of the tragus and transitions toward the lobule. Alternatively, a pretragal incision can be used that courses within the preauricular skin crease. In male patients this incision is positioned approximately 1 cm anterior to the preauricular crease to avoid having hair-bearing skin placed adjacent to the auricle.

The lobule incision can be variably positioned. In patients with a 'hanging' lobule, the incision can be placed 1–2 mm below the lobule attachment and readily camouflaged. If a dependent lobule is not present, the incision is made at the junction of the lobule and infra-auricular skin. The lobule incision extends onto the posterior surface of the auricle coursing over the conchal bowl. Approximately 3–5 mm should remain between the incision and the post-auricular sulcus. In the male patient, the incision rests within the sulcus to avoid displacing hair-bearing skin onto the ear. The incision extends to the level of the fossa triangularis before turning posteriorly. A less dependent skin flap can be created in patients with a smoking history by limiting the superior extent of this incision. A V-shaped dart is created as the incision

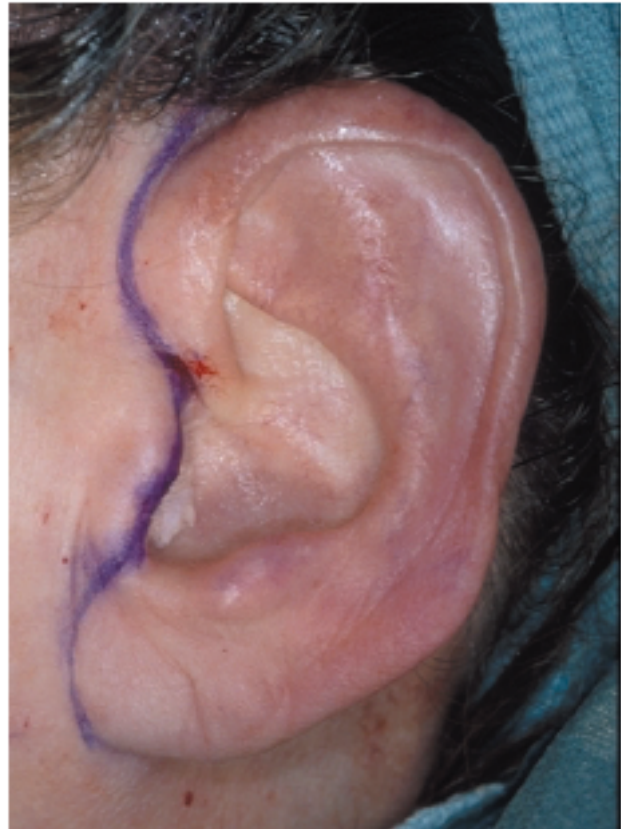

Figure 222.1 The post-tragal incision is placed just behind the tragal cartilage. Note how the outline of the tragus is defined by the incision.

traverses the sulcus and minimizes postoperative webbing (**Figure 222.2**). The incision extends into the hair-bearing skin before coursing parallel to the occipital hairline.

Elevation of the skin flap begins in the post-auricular region. The flap is elevated in an avascular plane while preserving the subdermal plexus and a thin fatty layer on the undersurface of the skin. Elevation continues into the neck in a supra-platysmal plane. The preauricular skin flap is elevated in a similar manner. Near the zygomatic arch, dissection is limited to the posterior one-third of the arch to avoid potential frontal nerve injury. A full-thickness skin flap is elevated off the tragal cartilage. This facilitates redraping of the skin and helps maintain the natural tragal contour. The preauricular skin flap is elevated approximately 9 cm anteriorly and can be extended over the jawline into the neck. Dissection in the neck is most commonly performed in the subcutaneous plane. In many patients, liposuction of the neck can be performed without connecting the preauricular with the neck dissection.

Once the skin flap is elevated, the SMAS is identified. A horizontal incision is made in the SMAS just below and parallel to the zygomatic arch but limited to the posterior

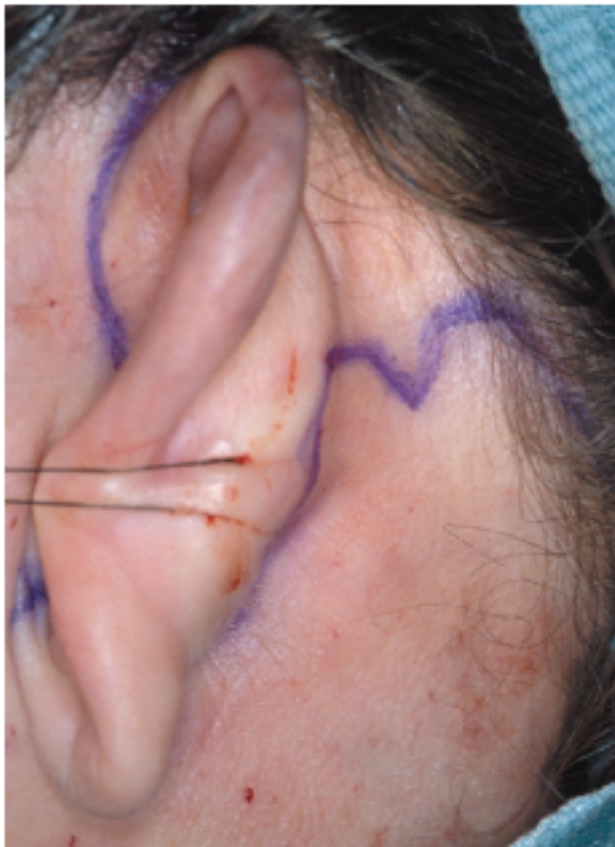

Figure 222.2 The post-auricular incision runs along the posterior surface of the conchal cartilage with a V-shaped dart in the posterior limb of the incision as it moves toward the hairline. This dart acts to break up the scar and prevent scar contracture.

one-third segment (**Figure 222.3**). This connects to a vertical limb coursing 2 cm anterior to the tragus. The SMAS incision should not extend beyond the angle of the mandible because the marginal mandibular nerve is in close proximity. The SMAS flap is elevated approximately 3–5 cm. In many cases the platysma is incorporated as an extension of the SMAS. The SMAS flap is then advanced and primarily pulled in a superior vector with a slight posterior vector. Maximal pull should be avoided when suspending the first side as this may restrict mobility of the contralateral side and result in facial asymmetry. A triangular segment of SMAS is excised and the edges of the SMAS flap are then sutured to the dense fibrous tissue at the inferior margin of the zygomatic arch and the preauricular SMAS. Multiple 4-0 PDS and 5-0 nylon sutures can be used for this SMAS imbrication. In some patients, a post-auricular SMAS flap can be dissected and suture plicated to the mastoid periosteum.

After tightening the SMAS, the skin flap advances easily over the face. The post-auricular skin is pulled superiorly and slightly anteriorly, whereas the preauricular skin is pulled superiorly and slightly posteriorly. The post-auricular skin is temporarily anchored at its superior margin with staples. Similarly, the superior margin of the preauricular skin is anchored to the temporal hair line. After careful measurement, the excess skin is sharply trimmed. The tragal skin flap should be thinned sufficiently to allow natural redraping over the cartilage (**Figure 222.4**). It is imperative to avoid excess skin tension as displacement of the tragus can easily result. Meticulous care should be taken to realign the occipital and temporal hairline.

Attention is then focused on the portion of the skin flap hammocking the lobule. The skin is sharply divided to ‘release’ the lobule leaving a significant hammock effect on the lobule. This support on the lobule will help prevent a satyr ear deformity due to postoperative settling of the earlobe. The excess skin is trimmed to recreate a natural lobule contour. It is important to minimize tension placed on this closure.

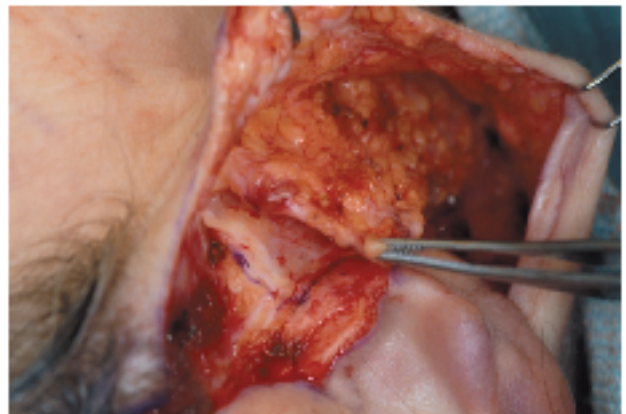


Figure 222.3 The SMAS flap is elevated just below the zygomatic arch and elevated anteriorly and inferiorly.

The entire incision is closed in a layered fashion over a 1/4 inch penrose or suction drain. The subcutaneous layer is closed with 5-0 polydioxanone sutures. The temporal, preauricular and lobule skin segments are closed with 6-0 nylon vertical-mattress sutures. The post-auricular skin is closed with 5-0 fast-absorbing plain gut suture. Antibacterial ointment is applied to all incision lines followed by a dry gauze pressure dressing.

All rhytidectomy patients are observed overnight. The following morning, the drain is removed and a pressure dressing is reapplied. Antibiotics are prescribed for a total of ten days postoperatively. Sutures are removed seven to

ten days after surgery. Oedema resolves over several weeks and facial contour stabilizes at approximately four to six weeks after surgery (**Figure 222.5**). Erythema of the tragal incision should fade over several months.

SUBMENTAL LIPOSUCTION AND PLATYSMAPLASTY

When indicated, submental liposuction and platysmaplasty are performed prior to the rhytidectomy. A midline incision is made within the first well-developed submental skin crease posterior to the mandible. If liposuction alone is planned, this is limited to a 5 mm stab incision. If a wider incision is later needed for platysmaplasty, the stab incision should be made initially to maintain vacuum pressure during liposuction.

A wide variety of liposuction cannulas exists, ranging from flat to round-tipped with an array of suction port designs. Surface irregularities appear to be minimized with the use of smaller cannulas. We prefer pre-tunnelling with a 2 mm cannula followed by applied low suction. The cannula is inserted into the subcutaneous space between the dermis and platysma. The dominant hand controls movement of the cannula while the contralateral hand guides tip position. Pre-tunnelling involves limited dissection to facilitate passage of the larger cannula. Liposuction is performed by dissecting with the cannula in radial fashion away from the incision. One atmosphere (760 mmHg) of negative pressure is usually sufficient. The suction port should always be directed away from the skin to minimize dermal trauma and dimpling. Uniform suctioning is performed across the submental triangle down to the hyoid bone. Liposuction should be limited near the inferior border of the mandible to avoid injuring the marginal mandibular nerve. Periodic inspection of skin using the 'pinch and roll' technique helps determine the degree and extent of liposuction required. A sufficient amount of fat should remain to maintain natural skin cushioning.

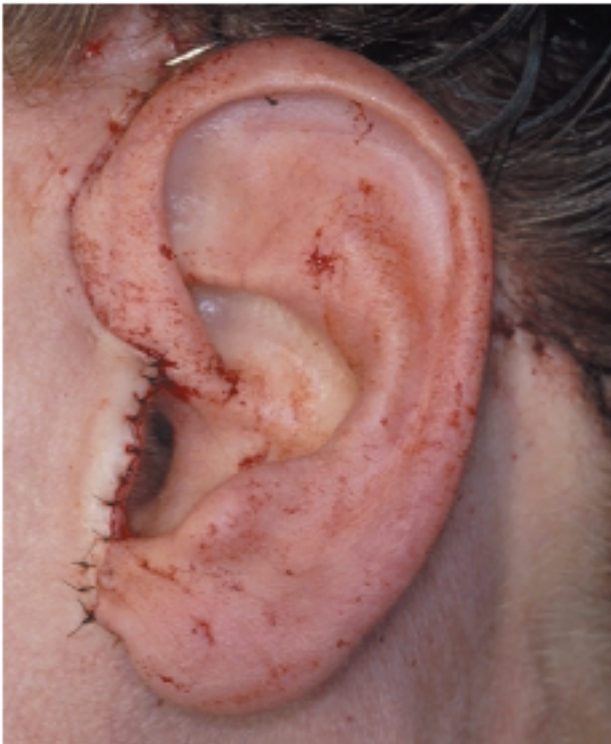

Figure 222.4 The post-tragal closure requires that the skin flap over the tragus is tension free. Removal of subcutaneous fat on the tragal flap will ensure good tragal definition.

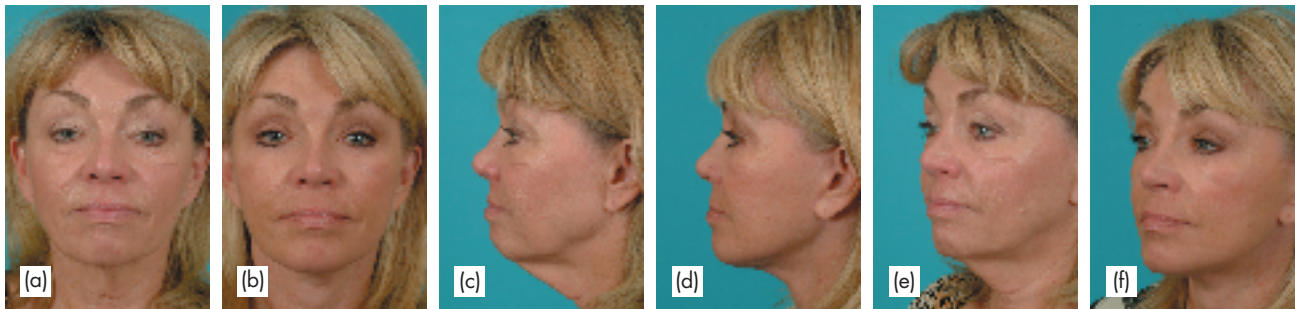

Figure 222.5 This patient underwent rhytidectomy with SMAS imbrication. Chin augmentation was also performed to provide better skeletal support. (a) Preoperative frontal view; (b) postoperative frontal view; (c) preoperative lateral view; (d) postoperative lateral view; (e) preoperative oblique view; (f) postoperative oblique view.

Platysmaplasty requires creation of a slightly wider submental incision. Blunt scissor dissection is used to expose the medial border of the platysma muscles. Residual fat surrounding the incision and in between the muscles is removed under direct vision. If minor platysmal banding is present, plication of the exposed muscle borders across a short distance is sufficient to improve the submental contour. In patients with severe platysmal banding, both muscles are horizontally incised at the level of the hyoid bone. The muscles are then plicated anterior to this incision, thereby recreating a well-defined cervico-mental angle (**Figure 222.6**). The submental incision is closed in a layered fashion.

COMPLICATIONS

Haematoma

Haematoma formation is the most common complication of rhytidectomy. In most modern series, the incidence of haematoma is reportedly less than 4 percent.⁸ A majority occur within 48 hours postoperatively and often within the initial six to eight hours. Poor hemostasis, extended skin flaps and severe hypertension⁹ have all been purported to be influential factors. Some haematomas are so small they are considered clinically insignificant and can be observed expectantly. Others result in discrete pooling that should be addressed in a timely manner with aspiration using a large-bore needle. Alternatively, a small stab incision made within a well-developed skin crease will allow adequate drainage. Application of a pressure dressing may help in preventing recurrent formation.

An expanding haematoma is a surgical emergency requiring immediate attention. This is heralded by acute swelling, pain and discolouration along the buccal surface. All surgical dressings must be removed and the

skin flaps inspected closely. If flap viability is in question, the immediate removal of consecutive sutures may temporarily restore adequate circulation. Exploration of the wound and evacuation of all visible clot, preferably in the operating room, is mandatory. In a majority of cases, the specific source of bleeding is never identified.¹⁰ Nonetheless, failure to recognize and treat hematoma can result in abnormal pigmentation, alopecia, skin puckering and flap necrosis.

Nerve damage

Nerve damage resulting from rhytidectomy is a rare occurrence. Baker and Conley reported a 0.1 percent incidence of permanent nerve damage in a series of 6500 rhytidectomies.¹¹ The most commonly injured branch is the great auricular nerve. Mechanisms of injury include inadvertent dissection deep to the sternocleidomastoid fascia, plication of the post-auricular SMAS and transmission of thermal electrocautery. In most cases, the integrity of the nerve has not been disrupted and full return of sensation can be expected.

Branches of the facial nerve are the most commonly injured motor nerves in rhytidectomy. Proximity to the plane of dissection, especially during elevation of the SMAS, makes them particularly vulnerable to mechanical injury. The frontal nerve is most often injured during SMAS elevation near the zygomatic arch. Within this region, the frontal nerve becomes increasingly superficial as it courses over the middle segment of the arch. If surgical dissection is limited to the posterior one-third of the arch, risk to the frontal nerve branch is virtually negated. Injury to the marginal mandibular nerve typically results from transection of the platysma or excess SMAS retraction near the angle of the mandible. Fortunately, nearly 85 percent of paralyzed motor branches will recover spontaneously with minimal residual deficits.

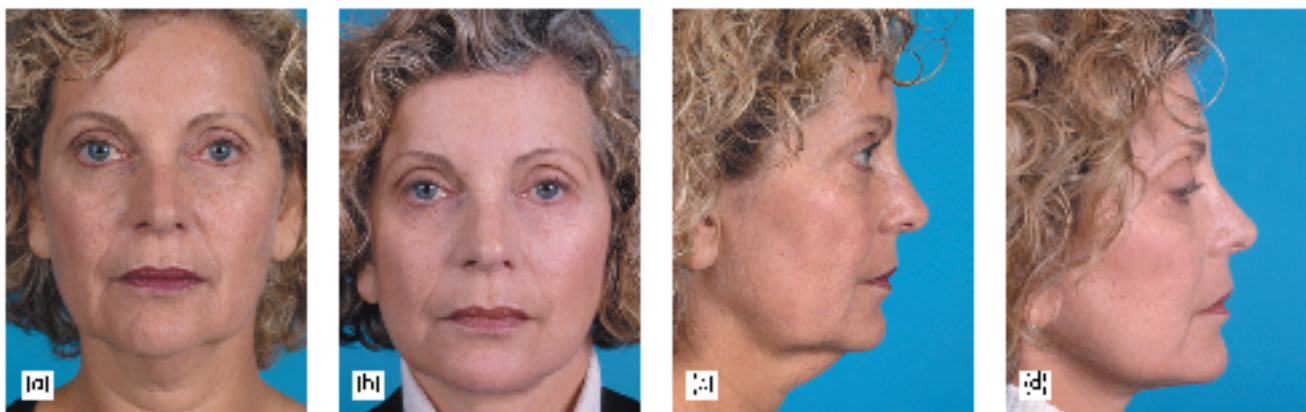

Figure 222.6 This patient underwent rhytidectomy with submental liposuction. The platysma muscle was plicated in the midline to correct the platysmal banding. (a) Preoperative frontal view; (b) postoperative frontal view; (c) preoperative lateral view; (d) postoperative lateral view.

Skin slough

Skin slough most commonly arises as a consequence of unrecognized and untreated haematoma. Excess skin tension and disruption of the subdermal plexus are also frequent causes. The toxic effects of smoking have long been recognized as another predisposing factor in skin sloughing.¹² The post-auricular flap is at greatest risk because skin tension is typically highest in this region. Dependent flap length is also maximal and the skin is relatively thin along this surface. In general, expectant management with meticulous wound care is the rule for skin sloughing. However, frequent visits and repeated patient reassurance are necessary. Superficial epidermal sloughing typically results in an acceptable appearance after healing. In cases of full-thickness sloughing, eschar formation is seen and serial debridement is required to promote healing by secondary intention. Invariably, patients with full-thickness loss can expect some degree of hypertrophic scarring and abnormal pigmentation.

Alopecia

Alopecia in the temporal region is a common complication of rhytidectomy and one that is easily avoided with careful incision design and placement. In some cases alopecia is a transient phenomenon, termed telogen effluvium, attributed to temporary follicular shock. In other instances alopecia is more permanent, for example, when the hair follicles have been injured by thermal electrocautery. If no evidence of regrowth is noted after a waiting period of four to six months, hair restoration can be attempted using either micrografts or local skin flaps.

Satyr ear deformity

Satyr ear, or 'devil's ear' deformity, results from improper incision placement around the lobule and/or overzealous excision of the skin flap. Tension caused by postoperative relaxation of skin leads to an inferior displacement of the lobule and abnormal banding. This complication can be avoided by preserving a tight supporting margin of skin below the lobule attachment that actually pulls up on the lobule.

KEY POINTS

- Sun damage to the skin, atrophy of tissues and the effects of gravity bring on the changes seen in the ageing face patient.
- Preoperative analysis is critical to determine the specific needs of the patient.

- Incision placement is critical to help hide incisions and avoid deformity of the hairline.
- Patients must stop smoking cigarettes weeks before surgery to avoid vascular compromise and necrosis of skin flaps.
- Dissection of the skin flaps should be just below the level of the subdermal plexus.
- Dissection of the SMAS allows correction of jowling over the body of the mandible and neck deformity. Placement of tension on the SMAS plication takes tension off the skin closure.
- The most commonly injured nerve in facelift surgery is the greater auricular nerve.
- The incidence of haematoma formation is less than 4 percent.
- Facelift surgery does not provide a long-lasting result as tissues tend to loosen over time.

Best clinical practice

- ✓ A post-tragal rhytidectomy incision is used in most female patients, while a pre-tragal incision is used most commonly in male patients.
- ✓ Elevation of the skin flap and SMAS layer should be limited to the posterior one-third of the zygomatic arch to avoid injuring the frontal nerve branch.
- ✓ The post-auricular skin flap is suspended superiorly and anteriorly, while the pre-auricular skin flap is suspended superiorly and posteriorly. It is imperative to avoid tension on any portion of the skin flap.
- ✓ Submental liposuction and/or platysmaplasty should be considered in patients with neck fullness not attributed to excess skin alone.
- ✓ Postoperative haematoma formation requires timely assessment and intervention to minimize chances of a suboptimal aesthetic outcome.

Deficiencies in current knowledge and areas for future research

- Advances in facelift surgery should make use of other methods of suspension to help provide a longer lasting result.
- In the future, nonsurgical intervention should be able to slow the process of ageing and decrease the need for invasive facelift surgery.

REFERENCES

1. Skoog T. *Plastic surgery: new methods and refinements*. Philadelphia, PA: WB Saunders Co, 1974.
2. Mitz V, Peyronie M. The superficial musculo-aponeurotic system (SMAS) in the parotid and cheek area. *Plastic and Reconstructive Surgery*. 1976; **58**: 80–8.
3. Yaar M, Gilchrist BA. Cellular and molecular mechanisms of cutaneous ageing. *Journal of Dermatologic Surgery and Oncology*. 1990; **16**: 915.
4. Zimble MS, Kokaska MS, Thomas JR. Anatomy and pathophysiology of facial aging. *Facial Plastic Surgery Clinics of North America*. 2001; **9**: 1–9.
5. Edgerton MT et al. Surgical results and psychological changes following rhytidectomy. *Plastic and Reconstructive Surgery*. 1964; **33**: 503–21.
6. Goin MK, Burgoyne RW, Goin JM. Face-lift operation: the patient's secret motivations and reactions to 'informed consent'. *Plastic and Reconstructive Surgery*. 1976; **58**: 273–9.
7. Rees TD, Aston SJ. Complications of rhytidectomy. *Clinics in Plastic Surgery*. 1978; **5**: 109.
8. Larrabee WF, Ridenour BD. Rhytidectomy: technique and complications. *American Journal of Otolaryngology*. 1992; **13**: 1–5.
9. Straith RE, Raju D, Hipps C. The study of hematomas in 500 consecutive facelifts. *Plastic and Reconstructive Surgery*. 1977; **59**: 694–8.
10. Pitanguy I, Ceravolo MP. Hematoma postrhytidectomy: how we treat it. *Plastic and Reconstructive Surgery*. 1981; **4**: 526–8.
11. Baker DC, Conley J. Avoiding facial nerve injury in rhytidectomy. *Plastic and Reconstructive Surgery*. 1979; **64**: 781–95.
12. Rees TD, Liverett DM, Guy CL. The effect of cigarette smoking on skin survival in the face lift patient. *Plastic and Reconstructive Surgery*. 1984; **73**: 911–5.